70 Hypertrichosis and Hirsutism

Rachel Reynolds, Kristen Corey and Francisco M. Camacho

Key features

- Hypertrichosis refers to excessive growth of hair anywhere on the body, whereas hirsutism represents excessive hair growth within androgen-dependent sites in girls and women
- Hypertrichosis may be generalized or localized, with etiologies ranging from genodermatoses to underlying hamartomas to repeated trauma
- Hirsutism is related to hormonal factors, in particular an increase in circulating androgen levels and/or enhanced sensitivity of hair follicles to androgens
- In women, the major sources of androgens are the adrenal glands and the ovaries; dysfunction of these organs must be considered when a patient presents with hirsutism
- Depending on its etiology, treatment of hirsutism may include oral contraceptives, antiandrogens, gonadotropin-releasing hormone agonists, glucocorticoids, and insulin-lowering agents, combined with topical medications and physical measures (e.g. laser hair removal)

HYPERTRICHOSIS

Introduction

Hypertrichosis describes the growth of excessive hair anywhere on the body. The term is frequently confused with hirsutism, which should only be applied to women with excessive growth of terminal hairs in androgen-dependent sites (i.e. a "male pattern") due to hyperandrogenemia or increased end-organ sensitivity to androgens[1–3]. Hypertrichosis can be classified based on its distribution (generalized versus localized), the age of onset (congenital or programmed from birth versus acquired), and the type of hair (lanugo or vellus versus terminal).

Clinical Features

Generalized hypertrichosis

In generalized hypertrichosis, there is lanugo hair, excess vellus hair, or terminal hair over much of the cutaneous surface, including an acquired transformation of terminal hair into lanugo hair (Fig. 70.1)[4]. Lanugo is the non-pigmented, non-medullated, fine hair that covers the fetus and can grow up to several centimeters in length; it is normally shed *in utero* at ~7–8 months' gestation or during the first few weeks of life and replaced by vellus hair on the body and terminal hair on the scalp. Some neonates, especially if born prematurely, transiently retain lanugo hairs diffusely and shed them during the first few weeks of life.

Congenital generalized hypertrichosis

A number of distinctive but rare genetic syndromes are associated with congenital generalized hypertrichosis (Table 70.1). While the majority of these disorders have extracutaneous manifestations such as gingival hyperplasia or facial dysmorphism, some have primarily hypertrichosis, including universal hypertrichosis. However, this latter entity is sometimes viewed as constitutional, i.e. simply exaggerated normal hairiness that may be familial. Genetic abnormalities associated with congenital generalized hypertrichosis lead to dysfunction of several proteins, ranging from those known to be involved in hair follicle development to membrane transporters (see Table 70.1).

The possibility of intrauterine exposure to medications (e.g. minoxidil) also needs to be considered in infants with congenital generalized hypertrichosis. The differential diagnosis also includes inherited disorders in which hypertrichosis can involve multiple sites and may appear early in life (Table 70.2).

Prepubertal hypertrichosis

Prepubertal hypertrichosis is a relatively common finding in otherwise healthy infants and children, most often occurring in individuals of Mediterranean or South Asian descent. Pigmented hair is present in a widespread, diffuse distribution and becomes more obvious during childhood. There is involvement of the face (especially the forehead, temples, and preauricular area), proximal extremities, and back; hairs in the latter location assume an "inverted fir tree" pattern. Bushy eyebrows and a low anterior hairline represent additional features.

The facial distribution pattern of prepubertal hypertrichosis can overlap with that of familial hirsutism (see below), and there may be a family history of excessive hairiness. Mildly elevated levels of total and free testosterone have been observed in a subset of girls with prepubertal hypertrichosis, while others have a normal androgen profile[12]. These findings suggest multiple etiologies for this clinical pattern of hypertrichosis, including androgen excess as well as an increased constitutional propensity for hair growth.

Acquired generalized hypertrichosis

Acquired generalized hypertrichosis is most often related to drug ingestion (Table 70.3). Drug-induced hypertrichosis is characterized by slow growth of terminal hair of medium thickness. The findings are most evident on the forehead, temples, flexor aspects of the extremities, and trunk. Drug-related hypertrichosis is usually reversible, and differs in distribution from drug-induced hirsutism.

Acquired generalized hypertrichosis can also represent a sign or consequence of a variety of systemic conditions, including disorders of the CNS (e.g. traumatic brain injuries), juvenile hypothyroidism, juvenile dermatomyositis, acromegaly (especially of the lower face), malnutrition (including anorexia nervosa), POEMS syndrome, and advanced HIV disease.

Acquired hypertrichosis lanuginosa

This is considered to be a paraneoplastic phenomenon as it is associated with internal malignancies, most often of the lung, colon, or breast. Occasionally, acquired hypertrichosis lanuginosa may precede the diagnosis of the neoplasm. In addition, it may be associated with other paraneoplastic dermatoses, such as acanthosis nigricans, palmoplantar keratoderma, the sign of Leser–Trélat, and acquired ichthyosis (see Ch. 53). The lanugo hair appears over the entire body within a short period of time, although in mild forms it may be localized to the face, leading to a "simian" appearance. Lanugo hair may even develop in areas of androgenetic alopecia.

Localized hypertrichosis

Most cases of localized hypertrichosis involve a switch from vellus to terminal hair in sites that do not usually bear terminal hair. Localized hypertrichosis can develop as a component of a hamartoma, as an isolated congenital lesion, as a manifestation of a systemic disease (inherited or acquired), or as a consequence of cutaneous trauma or inflammation.

Congenital localized hypertrichosis

Hamartomas, including those with delayed clinical presentation, and congenital abnormalities characterized by hypertrichosis of a specific anatomic site (Figs. 70.2 and 70.3; Tables 70.4 & 70.5) are included in this category.

Congenital melanocytic nevi and plexiform neurofibromas

Congenital melanocytic nevi often have associated hypertrichosis. The increased hair growth may be noted at birth, but often becomes

Downloaded for Anonymous User (n/a) at Egyptian Knowledge Bank from ClinicalKey.com by Elsevier on March 10, 2024. For personal use only. No other uses without permission. Copyright ©2024. Elsevier Inc. All rights reserved.

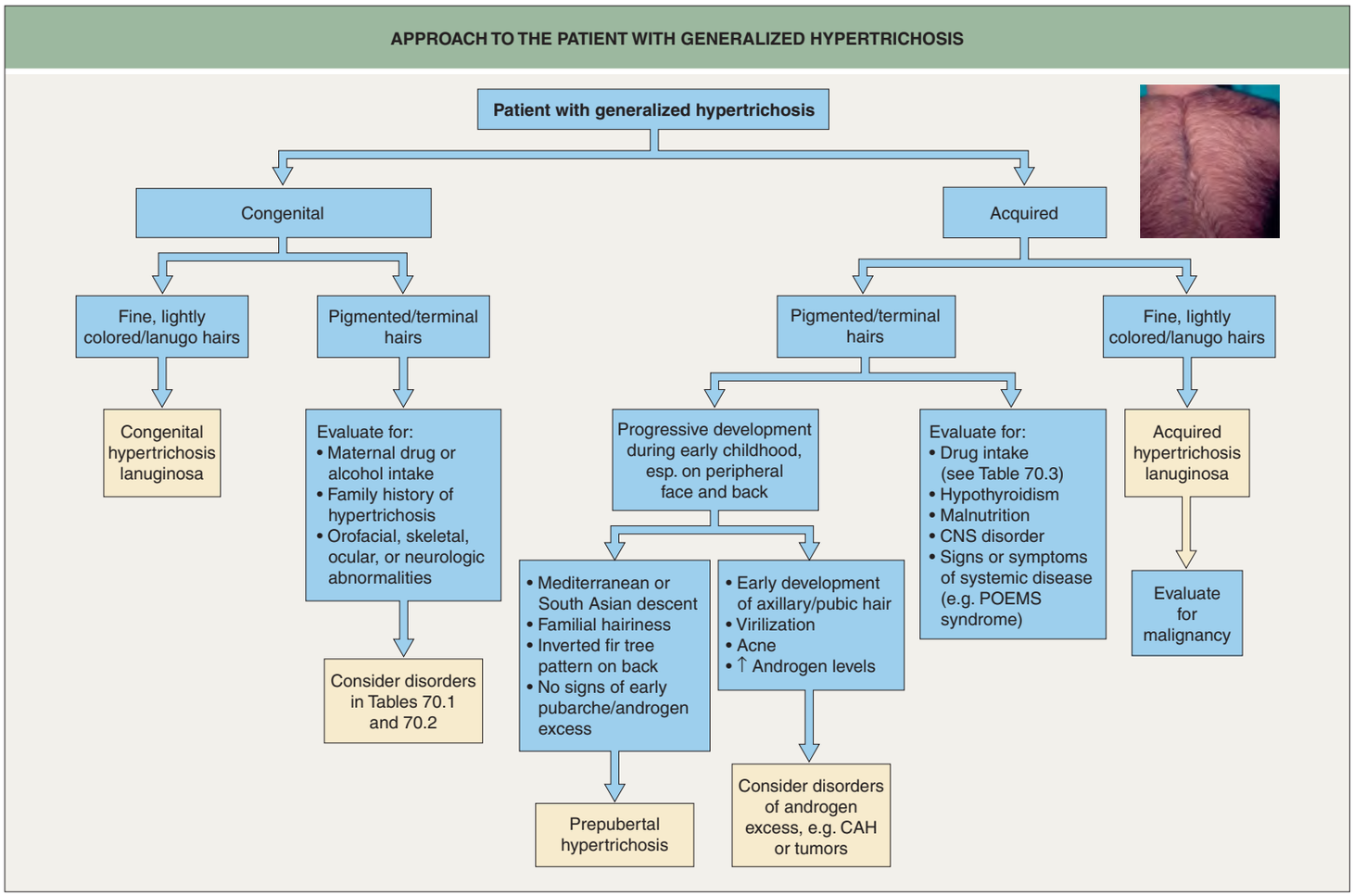

Fig. 70.1 Approach to the patient with generalized hypertrichosis. CAH, congenital adrenal hyperplasia; POEMS, *p*olyneuropathy, *o*rganomegaly, *e*ndocrinopathy, *m*onoclonal gammopathy, *s*kin lesions. The photograph is an example of universal hypertrichosis, which some authors view as simply exaggerated normal hairiness that may be familial.

more prominent during infancy or early childhood. Hypertrichosis can be seen in all sizes of congenital melanocytic nevi (see Ch. 112). A particularly dense growth of terminal hairs may accompany scalp nevi. Plexiform neurofibromas can also have associated hyperpigmentation and hypertrichosis.

Becker melanosis (nevus)

This is a hamartoma characterized by macular hyperpigmentation with irregular borders, most commonly located on the upper lateral trunk (anterior or posterior) (see Ch. 112). Some patients have associated hypertrichosis while others do not. The pigmentation usually arises during the first decade of life, whereas the hypertrichosis typically appears in the second decade (Fig. 70.5). Becker melanosis is most often diagnosed in boys and men. Postzygotic mutations in the *ACTB* gene encoding β-actin have been found to underlie Becker melanosis and associated anomalies (referred to as Becker nevus syndrome; see below) as well as smooth muscle hamartomas (see Ch. 117 and below)[15].

Occasionally, asymmetry of the extremities and hyperplasia or hypoplasia of the affected areas is evident, especially ipsilateral mammary hypoplasia in women or, less often, the Poland anomaly (unilateral chest wall hypoplasia and ipsilateral hand syndactyly). Rarely, there may be an association with genitourinary tract abnormalities (SNUB syndrome: supernumerary nipples, uropathies, Becker melanosis)[16]. Because of its benign nature, surgical removal of Becker melanosis is not recommended. Epilation can be performed by various techniques, but attempts at decreasing pigmentation via laser therapy are often not successful.

Smooth muscle hamartomas, which exist on a spectrum with Becker melanosis, may present as circumscribed hypertrichotic plaques with variable hyperpigmentation. A rare generalized form is characterized by extensive hypertrichosis and folding of the skin which has been reported under the term "Michelin tire baby" (see Table 97.7). Lastly, the hypertrichosis observed in the setting of hemimaxillofacial dysplasia (with facial asymmetry due to unilateral maxillary enlargement, gingival hyperplasia, and hypoplastic teeth) is often associated with Becker melanosis or smooth muscle hamartoma.

Other hamartomas and infantile tumors

Hypertrichosis can also overlie the following skin lesions: plaque-type blue nevus, neurocristic hamartoma, fibrous hamartoma of infancy, dermal dendrocyte hamartoma, eccrine angiomatous hamartoma, and tufted angioma.

Nevoid hypertrichosis

This is an uncommon congenital alteration characterized by the growth of terminal hairs in a circumscribed area. In general, there are no extracutaneous associations in *primary nevoid hypertrichosis*; the skin within the affected area is normally pigmented and there is no underlying hamartoma (Fig. 70.6). Table 70.4 outlines specific sites of localized hypertrichosis that can be familial. To date there is a report of one family with primary multifocal localized hypertrichosis[17]. Nevoid hypertrichosis has also been observed to follow the lines of Blaschko, as reported in female carriers of X-linked hypertrichosis (see Table 70.1).

Secondary nevoid hypertrichosis can be associated with lipodystrophy, hemihypertrophy, scoliosis, and abnormalities of the underlying vasculature. Nevoid hypertrichosis also occasionally occurs together with epidermal nevi or nevoid hypopigmentation, and it can represent a manifestation of Proteus and Happle–Tinschert syndromes.

Spinal dysraphism and the hair collar sign

Dysraphism is defined as an alteration of the formation of a fold or elevation which is constituted in the midline of the human body during

Downloaded for Anonymous User (n/a) at Egyptian Knowledge Bank from ClinicalKey.com by Elsevier on March 10, 2024. For personal use only. No other uses without permission. Copyright ©2024. Elsevier Inc. All rights reserved.

HEREDITARY DISORDERS CHARACTERIZED BY CONGENITAL GENERALIZED HYPERTRICHOSIS		
Disorder	**Inheritance (genetic basis/gene)**	**Other key features**
Increased hair is the major feature		
Congenital hypertrichosis lanuginosa	AD	• Fetal lanugo hair is not replaced by normal hair and continues to grow • Fine, downy, silvery-gray to blond lanugo hair that may be up to 10 cm in length • Involves entire body surface (except for the palms, soles, dorsal surface of distal phalanges, and prepuce) but hair may be shed over the first year of life • Occasional dental anomalies; rarely other associations (e.g. ear defects, glaucoma, pyloric stenosis, photophobia, ID)
Universal hypertrichosis	AD	• Thicker, longer hair most prominent on the back, proximal extremities and the frontal, temporal, and preauricular areas of the face* • Increases during infancy and tends to persist • Considered by some authors to be simply exaggerated normal hairiness that may be familial
Ambras syndrome (hypertrichosis universalis congenita, Ambras type; HTC1)[5,6]	AD (8q22–q24 breakpoints; position effect downregulates *TRPS1* expression)	• Fine, silky, lightly colored, long vellus hair involving the entire body but primarily the face, ears, and shoulders • Uniformly distributed on the face, including the nose • Persists for life • Minor facial dysmorphism, dental anomalies, supernumerary nipples
Generalized hypertrichosis with extracutaneous features		
X-linked hypertrichosis (congenital generalized hypertrichosis; HTC2)[7]	XLD (Xq27.1; palindrome-mediated interchromosomal insertion; position effect downregulates *FGF13* expression)	• Curly, shorter, dark hair most prominent on the face and upper body • Anteverted nostrils, prognathism; occasional dental anomalies, deafness • Female carriers may have nevoid hypertrichosis following lines of Blaschko
Congenital generalized hypertrichosis with or without gingival hyperplasia (HCT3)[8]	AD or AR (17q24.2–q24.3 microdeletion or microduplication [AD]; position effect downregulates *SOX9* expression; also *ABCA5* [AR])	• Dark terminal hairs on the peripheral face, central back, and extremities • In addition to gingival hyperplasia, coarse facies, ID, seizures
FHEIG syndrome	AD (*KCNK4*)	• *F*acial dysmorphism, *h*ypertrichosis, epilepsy, *I*D, *g*ingival overgrowth
Cantú syndrome (hypertrichotic osteochondrodysplasia)	AD (*ABCC9*)	• Coarse facies, osteochondrodysplasia, macrosomia at birth, cardiomegaly
Zimmermann–Laband syndrome	1: AD (*KCNH1*) 2: AD (*ATP6V1B2*) 3: AD (*KCNN3*)	• Gingival hyperplasia, coarse facies, hypoplastic nails and distal phalanges, joint hyperextensibility, splenomegaly, ID
Coffin–Siris syndrome†	1: AD (*ARID1B*) 2: AD (*ARID1A*) 3: AD (*SMARCB1*) 4: AD (*SMARCA4*) 5: AD (*SMARCE1*) 8: AD (*SMARCC2*) 9: AD (*SOX11*)	• Sparse scalp hair, coarse facies, hypoplastic fifth fingernails and toenails, GD, ID
Schinzel–Giedion midface retraction syndrome	AD (*SETBP1*)	• Midfacial vascular stain, midfacial retraction, hyperconvex nails, hypoplastic distal phalanges and dermatoglyphs, GU anomalies, GD, ID
Fontaine progeroid syndrome (includes Gorlin–Chaudry–Moss syndrome)	AD (*SLC25A24*)	• Craniofacial dysostosis with midfacial hypoplasia, hypoplastic distal phalanges, ocular and dental anomalies, genital hypoplasia, GD
Adducted thumbs syndrome	AR	• Arthrogryposis, craniosynostosis, myopathy
Barber–Say syndrome	AD (*TWIST2*)	• Lax skin, ectropion, macrostomia, coarse facies, hypoplastic nipples, GD

*This pattern of distribution is also observed in prepubertal hypertrichosis (see text).
†Protein products of mutated genes are subunits of the SWI/SNF complex.

Table 70.1 Hereditary disorders characterized by congenital generalized hypertrichosis. Autosomal recessive disorders presenting with congenital amaurosis or cataracts in addition to hypertrichosis have also been reported in individual families. ABC, ATP-binding cassette transporter; AD, autosomal dominant; AR, autosomal recessive; ARID, AT-rich interaction domain; ATP6V1B2, ATPase H^+ transporting V1 subunit B2; FGF, fibroblast growth factor; GD, growth delay; GU, genitourinary; HTC, hypertrichosis; ID, intellectual disability; KCN, potassium voltage-gated channel; SLC, solute carrier family; SMARC, SWI/SNF related, matrix associated, actin dependent regulator of chromatin; TRPS1, transcriptional repressor GATA binding 1/tricho-rhino-phalangeal syndrome 1 protein; TWIST, twist family BHLH transcription factor 2; XLD, X-linked dominant.

the union of two lateral portions. In spinal dysraphism, abnormal closure of the neural tube leads to defects in the vertebral column and/or spinal cord (see Ch. 64). Skin lesions marking a hidden vertebral defect are usually located in the dorsal midline. The faun tail is most often a sign of spina bifida occulta or diastematomyelia (split spinal cord), and is typically located in the lumbosacral region. In addition, a ring of hypertrichosis on the scalp, referred to as the hair collar sign, can surround membranous aplasia cutis or ectopic neural tissue, reflecting the origin of these midline lesions as incomplete neural tube defects.

Localized hypertrichosis in hereditary and acquired systemic diseases

There are multiple genetic diseases characterized by the presence of localized hypertrichosis as a major or secondary diagnostic feature (see Table 70.2). For example, hypertrichosis within sun-exposed areas is one of the signs of the porphyrias – in particular, porphyria cutanea tarda (Fig. 70.7) and hepatoerythropoietic porphyria. Likewise, the low frontal hairline and synophrys ("unibrow") in the Cornelia de Lange syndrome are important diagnostic features of that entity. Localized hypertrichosis

Downloaded for Anonymous User (n/a) at Egyptian Knowledge Bank from ClinicalKey.com by Elsevier on March 10, 2024. For personal use only. No other uses without permission. Copyright ©2024. Elsevier Inc. All rights reserved.

HEREDITARY DISEASES AND CONGENITAL SYNDROMES ASSOCIATED WITH REGIONAL HYPERTRICHOSIS		
Disorder	**Sites of hypertrichosis**	**Other key features**
Dysmorphic syndromes		
Cornelia de Lange syndrome	• Forehead, lateral face, shoulders, back • Low anterior hairline, synophrys, trichomegaly	• Distinctive facies, upper extremity anomalies, microcephaly, GD, ID, "growling cry" • AD (1,3,4): *NIPBL* > *SMC3*, *RAD21* • XLD (2,5): *SMC1A*, *HDAC8*
Rubinstein–Taybi syndrome	• Lateral face, shoulders, back • Thick eyebrows, trichomegaly	• Midfacial vascular stains, keloids, pilomatricomas • Broad thumbs/halluces, beaked nose, high-arched palate, short stature, ID • AD; *CREBBP* > *EP300*
KINSSHIP syndrome	• Extremities	• Horseshoe *ki*dney, *N*ievergelt/*S*avarirayan mesomelic dysplasia, *s*eizures, *h*ypertrichosis, *I*D, *p*ulmonary anomalies • AD (*AFF3*)
Disorders with primary cutaneous features		
Porphyrias	• Sun-exposed areas • Favors lateral face in PCT, HEP, VP • Face, trunk, extremities in CEP	• See Ch. 49
Lipodystrophy syndromes (e.g. Berardinelli–Seip syndrome, leprechaunism)	• Face, neck, extremities • Low hairline	• See Ch. 101
Superficial epidermolytic ichthyosis (SEI)*, erythrokeratodermia variabilis et progressiva (EKVP)	• Extremities (SEI); trunk and extremities (EKVP)	• See Ch. 57
Dystrophic epidermolysis bullosa*	• Areas of previous blistering	• See Ch. 32
Metabolic disorders		
Mucopolysaccharidoses†	• Trunk, extremities	• See Ch. 48
Congenital hypothyroidism	• Back, extremities	• See Ch. 46
Mitochondrial disorders		
Leigh syndrome due to *SURF1* mutations	• Forehead, extremities	• Progressive neurodegeneration
MELAS syndrome	• Lower extremities	• *M*itochondrial *e*ncephalopathy, *l*actic *a*cidosis, and stroke-like episodes
Intrauterine exposures‡		
Fetal hydantoin syndrome	• Face, back, extremities	• Gingival hyperplasia, coarse facies, hypoplastic nails and distal phalanges, GD
Fetal alcohol syndrome	• Face, back, extremities	• Midfacial hypoplasia, GD, CNS anomalies
Morpheaform or sclerodermoid disorders		
MONA (*m*ulticentric *o*steolysis, *n*odulosis, and *a*rthropathy; previously known as Winchester syndrome)	• Hypertrichosis and hyperpigmentation overlying areas of skin thickening	• Gingival hyperplasia, carpal/tarsal osteolysis, osteoporosis, coarse facies, GD • AR; *MMP2* (matrix metalloproteinase-2)
Histiocytosis-lymphadenopathy plus syndrome¶ (including H syndrome)[9–11]	• Lower trunk and lower extremities (in association with areas of *h*yperpigmentation & induration) • Histologic features in areas of induration include a polyclonal perivascular lymphohistiocytic infiltrate with numerous plasma cells in the dermis and subcutis	• Sensorineural *h*earing loss, short *h*eight, *h*eart anomalies, *h*epatosplenomegaly, scrotal masses, hypergonadotropic *h*ypogonadism, antibody-negative insulin-dependent diabetes mellitus, facial telangiectasias • AR; *SLC29A3* (encodes nucleoside transporter hENT3 which localizes to lysosomes and mitochondria)
Stiff skin syndrome	• Variable	• See Ch. 43
Linear melorheostosis (isolated melorheostosis)§	• Overlying affected skin and bone	• Hyperostosis ("candle wax" appearance) with overlying scleroderma • Isolated cases due to *LEMD3* mutations

*Hypertrichosis is an uncommon feature.
†Hypertrichosis may also be observed in other lysosomal storage diseases, e.g. Krabbe disease and GM1-gangliosidosis, as well as sialuria.
‡Also minoxidil and diazoxide.
¶Includes pigmented hypertrichosis with insulin-dependent diabetes mellitus (PHID) syndrome, sinus histiocytosis with massive lymphadenopathy (SHML), and Faisalabad histiocytosis as well as H syndrome.
§Hypertrichosis has also been described overlying linear scleroderma in the absence of melorheostosis.

Table 70.2 Hereditary diseases and congenital syndromes associated with regional hypertrichosis. Varying degrees of hypertrichosis (predominantly facial or generalized) have also been observed in children with chromosomal anomalies, e.g. partial trisomy of 1q, 3q, 4p, or 17q. Autosomal recessive palmoplantar keratoderma and exuberant curly scalp hair due to *FAM83G* mutations has also been reported. *NIPBL*, *SMC1A*, *SMC3*, and *RAD21* encode components of the cohesin complex. *RAD21* and *EP300* encode a histone acetyltransferase and a histone deacetylase, respectively. AD, autosomal dominant; *AFF3*, ALF transcription elongation factor 3; AR, autosomal recessive; CEP, congenital erythropoietic porphyria; GD, growth delay; HEP, hepatoerythropoietic porphyria; ID, intellectual disability; PCT, porphyria cutanea tarda; VP, variegate porphyria; XLD, X-linked dominant.

Downloaded for Anonymous User (n/a) at Egyptian Knowledge Bank from ClinicalKey.com by Elsevier on March 10, 2024. For personal use only. No other uses without permission. Copyright ©2024. Elsevier Inc. All rights reserved.

may also be observed in acquired systemic diseases, such as infrapatellar hypertrichosis in juvenile dermatomyositis or hypertrichosis overlying pretibial myxedema, indurated plaques of Rosai–Dorfman disease, and areas affected by the complex regional pain syndrome.

Acquired localized hypertrichosis

After repeated trauma, friction, irritation, or inflammation, the hair within affected areas of skin may become longer and thicker (e.g.

HYPERTRICHOSIS DUE TO DRUGS	
Antibiotics	
• Streptomycin	
Anticonvulsants	
• **Phenytoin**	
Anti-inflammatory drugs	
• Benoxaprofen	• Corticosteroids
Antiseptic agents	
• Hexachlorobenzene	
Chelators	
• Penicillamine	
Diuretics	
• Acetazolamide	
Immunosuppressives	
• **Cyclosporine**	• Mycophenolate mofetil
Psoralens	
• Methoxypsoralen	• Trimethylpsoralen
Vasodilators	
• Diazoxide • **Minoxidil**	• Prostaglandin E1
Other	
• Interferon-α • Fenoterol	• EGFR inhibitors (e.g. cetuximab, panitumumab, erlotinib, gefitinib) • IL-17 inhibitors (e.g. secukinumab, ixekizumab)

Table 70.3 Hypertrichosis due to drugs. Most common drugs are in **bold**. EGFR, epidermal growth factor receptor.

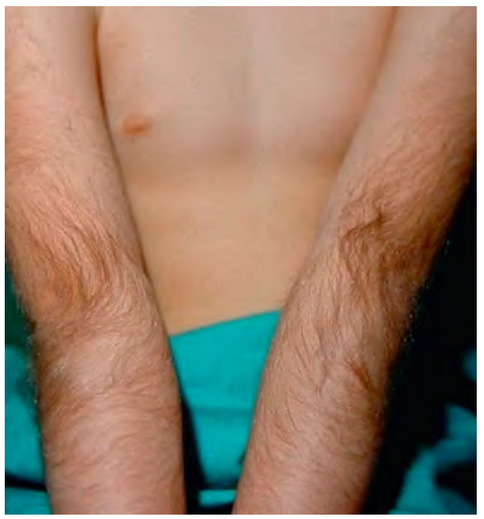

Fig. 70.2 Hypertrichosis cubiti. Multiple terminal hairs on both elbows in a child.

Fig. 70.3 Anterior cervical hypertrichosis. *Courtesy Harvey Lui, MD.*

HEREDITARY HYPERTRICHOSIS AFFECTING SPECIFIC ANATOMIC SITES			
Condition	**Inheritance**	**Onset**	**Other features**
Hypertrichosis cubiti (Fig. 70.2)	AD	Birth to early childhood	• Short stature* • Wiedemann–Steiner syndrome: short stature, facial dysmorphism, ID; *KMT2A*
Hairy palms and soles	AD	Birth	
Hypertrichosis of the auricle	AD†	Childhood or adolescence	• Primarily affects males
Hypertrichosis of the eyebrows	?	Adolescence	
Trichomegaly of the eyelashes	AR	Childhood	
Hypertrichosis of the nasal tip	?	Adolescence	• Primarily affects males
Anterior cervical hypertrichosis[13] (Fig. 70.3)	AD‡	Birth to early childhood	• Sensory and motor neuropathy, ID* • Hallux valgus*
Posterior cervical hypertrichosis	AD	Birth	• Kyphoscoliosis
Polythelia, including the hairy variant¶,[14]	AD§	Adolescence	• Urinary tract anomalies*

*Occasional finding.
†Shown not to be Y-linked in a cohort of Indian men; congenital hypertrichosis of the pinna can be seen in the offspring of diabetic mothers and in individuals with XYY syndrome.
‡Possible AR inheritance in a consanguineous family.
¶Tuft of hair along the "mammary line".
§Approximately 10% of cases are familial.

Table 70.4 Hereditary hypertrichosis affecting specific anatomic sites. Localized hypertrichosis as a sign of spinal dysraphism is discussed in Ch. 64. AD, autosomal dominant; AR, autosomal recessive; ID, intellectual disability; KMT2a, lysine-specific methyltransferase 2 A.

Downloaded for Anonymous User (n/a) at Egyptian Knowledge Bank from ClinicalKey.com by Elsevier on March 10, 2024. For personal use only. No other uses without permission. Copyright ©2024. Elsevier Inc. All rights reserved.

HYPERTRICHOSIS OF THE EYEBROWS AND EYELASHES
Synophrys ("unibrow")
• Isolated trait • Waardenburg syndrome (see Ch. 66) • Cornelia de Lange syndrome (see Table 70.2) • Zimmerman–Laband syndrome (see Table 70.1) • Mucopolysaccharidoses (see Ch. 48)
Inherited and/or congenital trichomegaly
• Trichomegaly due to *FGF5* mutations (AR) • Oliver–McFarlane syndrome* • Cornelia de Lange and Rubinstein–Taybi syndromes (see Table 70.2) • Congenital hypertrichosis lanuginosa and Ambras syndrome (see Table 70.1) • Cantú, Coffin–Siris, and Barber–Say syndromes (see Table 70.1) • Hermansky–Pudlak syndrome (see Ch. 66) • Kabuki and floating harbor syndromes† • Fetal alcohol syndrome (see Table 70.2)
Acquired trichomegaly
• HIV infection • Systemic medications: cyclosporine, EGFR inhibitors (e.g. cetuximab, gefitinib; Fig. 70.4), topiramate, tacrolimus, interferon-α • Ophthalmic medications: latanoprost, bimatoprost • Hypothyroidism • Porphyrias • Dermatomyositis, systemic lupus erythematosus • Malnutrition, anorexia nervosa
Distichiasis (double row of eyelashes)
• Lymphedema–distichiasis syndrome‡ • Setleis syndrome (double upper and absent lower lashes; see Ch. 64)
*Autosomal recessive (AR) disorder also featuring sparse scalp hair, intellectual disability, short stature, and retinal pigmentary degeneration. †Autosomal dominant (AD) disorders featuring distinctive facies, growth delay, and, in the former, intellectual disability. ‡AD condition due to FOXC2 mutations (see Ch. 104).

Table 70.5 Hypertrichosis of the eyebrows and eyelashes. EGFR, epidermal growth factor receptor.

Fig 70.4 Epidermal growth factor receptor inhibitor-induced trichomegaly. The eyelashes increased in both length and disorder after treatment with erlotinib. *Courtesy Edward Cowen, MD.*

hypertrichosis of the back in sack carriers, hypertrichosis of a fractured limb after the application of a plaster cast, hypertrichosis of the posterior neck in people who bear heavy weights; Fig. 70.8)[18]. Chronic rubbing or scratching can also lead to localized hypertrichosis. Transient localized hypertrichosis has been observed within vaccination sites and varicella scars as well as sites of wart removal and laser epilation[19]. In addition, hypertrichosis has been described overlying lipoatrophy following lupus panniculitis and within resolving lesions of psoriasis and morphea. Extractable hairs mimicking hypertrichosis are often evident within a pilonidal sinus (cyst), which is usually located within the gluteal cleft.

Fig. 70.5 Becker melanosis (nevus) on the mid back in a young man. In addition to hyperpigmentation, there is marked hypertrichosis. The degree of hypertrichosis can vary (see Ch. 112). When it is marked as in this patient, the clinical differential diagnosis includes congenital melanocytic nevus, especially when there is an underlying smooth muscle hamartoma.

Fig. 70.6 Nevoid hypertrichosis (nevus pilosus) of the scalp in a young boy. There was no underlying melanocytic nevus or hyperpigmentation. *Courtesy Jean L. Bolognia, MD.*

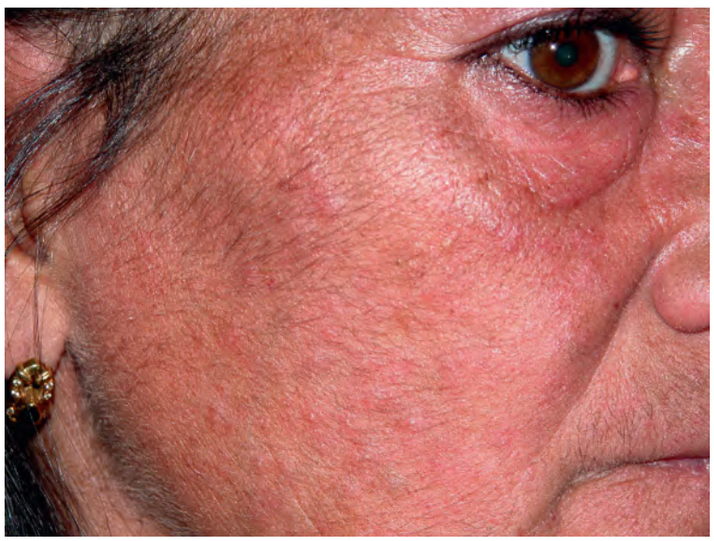

Fig. 70.7 Facial hypertrichosis in a woman due to porphyria cutanea tarda. *Courtesy Luis Requena, MD.*

Downloaded for Anonymous User (n/a) at Egyptian Knowledge Bank from ClinicalKey.com by Elsevier on March 10, 2024. For personal use only. No other uses without permission. Copyright ©2024. Elsevier Inc. All rights reserved.

Fig. 70.8 Acquired localized hypertrichosis. Hypertrichosis, hyperpigmentation, and epidermal hyperplasia at the site of friction.

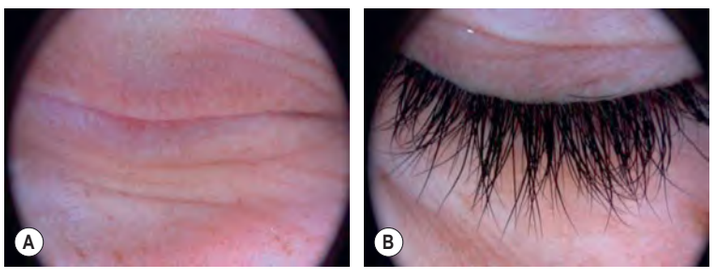

Fig. 70.9 Treatment of eyelash alopecia in a patient with alopecia universalis. A Prior to treatment. **B** Following daily application of topical latanoprost ophthalmic 0.005% solution for 6 months, there was regrowth of eyelashes.

Localized hypertrichosis has been reported after PUVA therapy. Sites of application of potent topical corticosteroids, tacrolimus, and creams containing mercury or iodine can also develop localized hypertrichosis, as can sites of repeated irritation from anthralin. Prostaglandin F-2α analogues (e.g. latanoprost, bimatoprost), which are topical agents used for the treatment of glaucoma, can induce trichomegaly of the eyelashes as well as brown iris pigmentation. The FDA has approved bimatoprost 0.03% solution for the stimulation of eyelash growth, and latanoprost has also been used off-label for this purpose (Fig. 70.9)[20].

Treatment

Methods available to treat hypertrichosis include chemical depilatory agents, electrolysis (see Ch. 140), and laser hair removal (see Ch. 137). Systems utilized for photoepilation include Nd:YAG, diode, and alexandrite lasers as well as intense pulsed light (IPL) sources (see Ch. 137). Barium sulfate depilatory creams have been shown to be especially effective, but they are odiferous and more irritating than calcium thioglycolate depilatory creams. Shaving and other physical methods (e.g. tweezing, waxing, threading, sugaring) may also be employed[21].

HIRSUTISM

Introduction

The term *"hirsutism"* is defined as excessive terminal hair growth in women that is within androgen-dependent sites (e.g. upper lip, chin, mid sternum, abdomen, back, buttocks; Fig. 70.10), representing a male distribution pattern. It reflects either hyperandrogenemia (an increase in circulating androgens) or an enhanced end-organ response to androgens[22–25]. Additional signs of hyperandrogenemia may include acne, a female pattern of androgenetic alopecia (see Ch. 69), irregular menstruation, and virilization. Virilization, which is uncommon and occurs with more severe hyperandrogenemia, also manifests with deepening of the voice, clitoromegaly, increased muscle mass, and male pattern hair loss (see Table 70.7).

Fig. 70.10 Idiopathic (constitutional) hirsutism. This patient had *s*eborrhea, *a*cne, *h*irsutism, and *a*lopecia, termed SAHA syndrome.

Epidemiology

Hirsutism, as defined by an abnormal score on the modified Ferriman and Gallwey scoring system (mFG; Fig. 70.11), affects ~5%–10% of women of reproductive age in the general population and rarely postmenopausal women[26,27]. In a study of North American women, 35% had terminal hairs on the linea alba, 17% in the periareolar area, 16% in the lumbosacral area, and 10% in the upper pubic triangle[23,24]. Androgen excess is present in >80% of premenopausal women with hirsutism, and ~70%–80% of these individuals have polycystic ovary syndrome (PCOS)[28]. Other women without hyperandrogenemia have idiopathic (constitutional) hirsutism, which tends to be relatively mild. Additional causes of hirsutism include drug intake, non-classic congenital adrenal hyperplasia, other endocrinopathies, and rarely androgen-secreting tumors (adrenal or ovarian; <0.3%) (Table 70.6). Women with rapid onset of hirsutism or signs of virilization are more likely to have an androgen-secreting tumor.

Classification

For clinical and therapeutic purposes, hirsutism can be classified according to the underlying causes (see Table 70.6)[23,24,29,30].

Clinical Features

Idiopathic (constitutional) hirsutism

Idiopathic (constitutional) hirsutism is a diagnosis of exclusion that is characterized by normal menses, normal ovaries on ultrasound, and no evidence of other causes. Androgen levels are usually normal but occasionally minimally elevated. Possible contributing factors include altered peripheral androgen activity and obesity[31], and this condition may be familial (Fig. 70.12). Approximately 5%–20% of all women with hirsutism and 50% of those with *mild* hirsutism have the idiopathic form[28]. Some women have acne and androgenetic alopecia as well as hirsutism, in association with slight increases in serum androgen levels (e.g. testosterone and dehydroepiandrosterone sulfate [DHEAS]). This constellation of findings has been referred to as *SAHA* – *s*eborrhea, *a*cne, *h*irsutism, and *a*ndrogenetic alopecia – *syndrome* (see Fig. 70.10)[32,33].

Ovarian hirsutism

Ovarian hirsutism can be of non-tumoral or tumoral origin. Non-tumoral etiologies include PCOS and ovarian hyperthecosis, with the former most common in premenopausal women and the latter typically occurring after menopause. A variety of benign or malignant ovarian tumors can also cause hirsutism, with malignant etiologies more likely to present with an abrupt onset of hirsutism, virilization, and markedly elevated testosterone levels.

Non-tumoral ovarian hirsutism

Polycystic ovary syndrome (PCOS)

This common syndrome, first described by Stein and Leventhal in 1935, affects ~5%–15% of women who are of reproductive age. It is

Downloaded for Anonymous User (n/a) at Egyptian Knowledge Bank from ClinicalKey.com by Elsevier on March 10, 2024. For personal use only. No other uses without permission. Copyright ©2024. Elsevier Inc. All rights reserved.

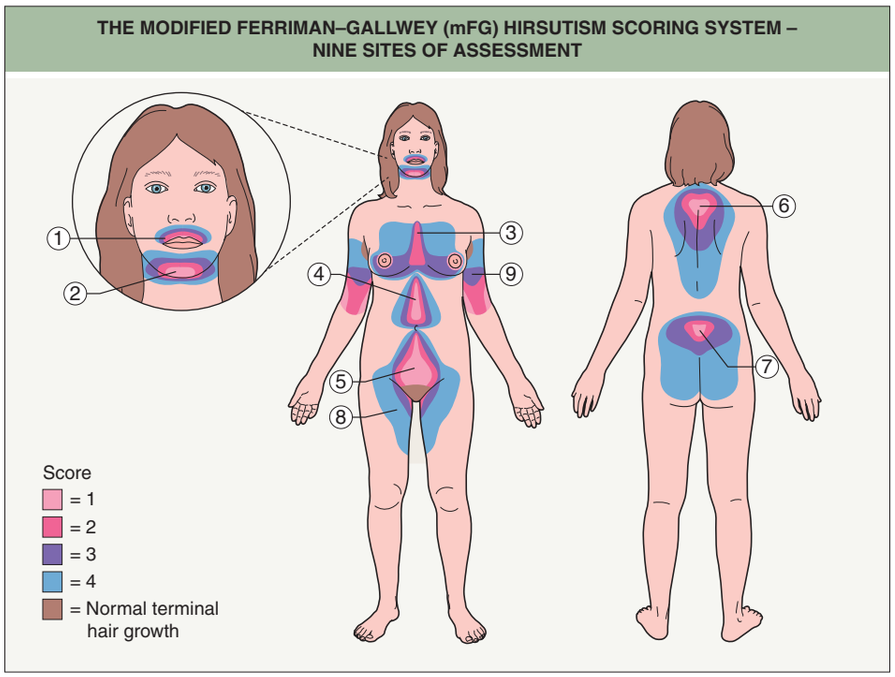

Fig. 70.11 The modified Ferriman–Gallwey (mFG) hirsutism scoring system – nine sites of assessment. The modified Ferriman and Gallwey score is based upon the sum of the values (graded from 0 to 4 points) for each of the nine body areas illustrated as follows: 0 points (no terminal hairs); 1 point (minimal terminal hairs); 2 points (hair growth is more than minimal but not yet that of a man); 3 points (hair growth is that of a man who is not very hairy); and 4 points (equivalent to a very hairy man). Total mFG scores that define hirsutism in reproductive-aged women vary depending upon race/ethnicity and are as follows: US and United Kingdom White or Black women, ≥8 (8–15 generally considered mild, 16–25 moderate, and >25 severe hirsutism); Mediterranean, Middle Eastern and Hispanic women, ≥9–10; South American women, ≥6; and Asian women, ranging from ≥2 for Han Chinese women to ≥7 for Southern Chinese women.

characterized by three major features (Rotterdam criteria): (1) oligo- or anovulatory cycles; (2) clinical or biochemical signs of hyperandrogenism (Fig. 70.13); and (3) ultrasonographic evidence of polycystic ovaries. Diagnosis requires two of these three criteria as well as exclusion of other causes of hirsutism (Fig. 70.14)[34]. Biochemically, there is typically a decrease in follicle-stimulating hormone (FSH) and an increase in luteinizing hormone (LH), as well as elevated serum levels of estrone and testosterone. Occasionally, serum prolactin levels are also increased.

After a normal menarche, patients develop persistent oligo- or amenorrhea that is frequently accompanied by infertility. Acne is present in 70% of patients and hirsutism in 90%. The associated hirsutism is usually lateral (i.e. on the breasts and lateral aspects of the face and neck) as well as on the central abdomen (see Fig. 70.13). Androgenetic alopecia in a female or male pattern is also commonly evident, but there are no signs of genital virilization. At least 50% of patients are obese, and some develop acanthosis nigricans and acrochordons in association with insulin resistance (see below). Patients with PCOS have large ovaries with a pearly gray surface, a thickened capsule and cysts with hyperplasia of the internal theca, but no signs of activity in the granulosa.

Women with PCOS have a higher prevalence of insulin resistance[35], dyslipidemia, hypertension, and obesity, which represent components of the "metabolic syndrome" that confers increased risk of atherosclerotic cardiovascular disease. Patients should be screened and followed for these conditions as well as non-alcoholic fatty liver disease (recently renamed metabolic dysfunction-associated steatotic liver disease), sleep apnea, endometrial cancer, and mood disorders, depending upon risk assessment (see Fig. 70.14)[34,36,37]. Although obesity, insulin resistance, and hyperandrogenemia are interconnected components of PCOS[37], it is important to note that insulin resistance also frequently occurs in non-obese patients with PCOS[38]. *HAIR-AN syndrome* characterized by hyperandrogenemia (*HA*), insulin resistance (*IR*), and acanthosis nigricans (*AN*) is now considered to represent a more severe subtype of PCOS that is more likely to result in type 2 diabetes, hypertension, and cardiovascular disease[39].

PCOS is oftentimes familial, but it is clearly a heterogeneous disorder. Attempts to identify its genetic basis have led to several possible candidate genes that could play a role in insulin resistance and androgen production, including those which encode cytochrome (CYP) 17, CYP 11A1, and insulin receptor substrate 1[37].

Ovarian hyperthecosis

This rare entity, which occurs primarily in postmenopausal women, is characterized by severe hyperandrogenism and insulin resistance. It results from differentiation of ovarian interstitial cells into steroidogenically active luteinized theca cells that overproduce testosterone. Women typically present with acne and hirsutism and are often virilized (Fig. 70.15). Serum testosterone levels are greatly elevated and result in increased peripheral estrogen production, which can increase the risk of endometrial carcinoma.

Tumoral ovarian hirsutism

Androgen-secreting ovarian tumors (e.g. Sertoli–Leydig cell, Leydig cell, steroid cell, and granulosa cell tumors) account for <5% of all ovarian neoplasms and can result in markedly elevated serum testosterone levels. Patients typically present with sudden onset and rapid progression of virilization in addition to hirsutism.

Adrenal hirsutism

Adrenal hirsutism can also be of non-tumoral or tumoral origin. The most frequent non-tumoral etiology is non-classic (mild) congenital adrenal hyperplasia. Androgen-secreting adrenal tumors are much less common and typically present in older women with abrupt onset and rapid progression of hirsutism and virilization[23–25].

Non-tumoral adrenal hirsutism – adrenal hyperplasias

Congenital adrenal hyperplasia (CAH) refers to a group of autosomal recessive disorders caused by genetic defects in enzymes involved in adrenal hormone production (Fig. 70.16). The most common type (≥95%) is *21-hydroxylase deficiency (21-OHD)* due to *CYP21A2* mutations, which has a broad range of clinical manifestations depending on the underlying *CYP21A2* defect. The classic (severe) form of 21-OHD CAH occurs in ~1 : 15 000 live births worldwide, whereas the non-classic (milder) form has a prevalence of ~1 : 200 to 1 : 2000 and is more common in certain ethnic groups, including women of Ashkenazi Jewish, Middle Eastern, and Indian heritage[40–43]. Other rare forms of CAH include those caused by defects in 11β-hydroxylase and 3β-hydroxysteroid dehydrogenase.

Classic CAH presents during the first 2 weeks of life with dehydration and electrolyte abnormalities (salt wasting) due to aldosterone as well as cortisol deficiency in ~75% of affected neonates. Female neonates with both salt-wasting and simple virilizing forms of classic CAH typically have ambiguous genitalia, while male neonates may manifest with subtle hyperpigmentation of the genitals, flexural areas, and palmoplantar creases. The US and many other countries have universal newborn screening programs for classic CAH based on detection of elevated levels of 17-hydroxyprogesterone, the preferred substrate for 21-hydroxylase[40,41]. As a result, affected neonates rarely present to a dermatologist[40,41].

Downloaded for Anonymous User (n/a) at Egyptian Knowledge Bank from ClinicalKey.com by Elsevier on March 10, 2024. For personal use only. No other uses without permission. Copyright ©2024. Elsevier Inc. All rights reserved.

CLASSIFICATION OF TYPES OF HIRSUTISM		
Type	**Notable lab abnormalities**	**Clinical findings/comments**
Idiopathic (constitutional) hirsutism		
Idiopathic hirsutism	Normal to slightly elevated serum androgen levels (testosterone, DHEAS)	• Normal ovaries on ultrasound • Normal menses • No identifiable cause • Idiopathic form often associated with obesity
Familial hirsutism (see Fig. 70.12)	Normal serum androgen levels	
Ovarian hirsutism		
Polycystic ovary syndrome (PCOS)	Normal to ↑ testosterone Normal DHEAS ↓ SHBG LH:FSH > 3	Defined by the presence of ≥2 of the following (see Fig. 70.14): • Chronic anovulation • Clinical or laboratory evidence of hyperandrogenism • Polycystic ovaries on ultrasound
Ovarian hyperthecosis	↑↑ testosterone Normal DHEAS	• Post- > premenopausal • Progressive severe hirsutism, virilization
Androgen-secreting ovarian tumor	↑↑ testosterone Normal DHEAS	• Rapid onset and progression of hirsutism, often with virilization • Post- > premenopausal
Adrenal hirsutism		
Classic (severe) congenital adrenal hyperplasia (CAH) due to 21-hydroxylase deficiency	↑↑ 17-OH progesterone ↑ androstenedione ↓ cortisol	• Presents during the neonatal period • Ambiguous genitalia in girls • May develop signs and symptoms of PCOS in adolescence if poorly controlled
Non-classic (mild) congenital adrenal hyperplasia (NCAH) due to 21-hydroxylase deficiency	↑17-OH progesterone Normal to slightly ↓ cortisol	• Clinical findings overlap with those of PCOS • Increased prevalence in certain ethnic groups (e.g. Ashkenazi Jews)
Androgen-secreting adrenal tumor	↑ to ↑↑ testosterone ↑↑ DHEAS ↑ cortisol ↓ ACTH	• Rapid onset and progression of hirsutism, often with virilization (carcinoma > adenoma)
Endocrinopathies that may be associated with hirsutism*		
Cushing syndrome	↑ to ↑↑ ACTH (pituitary adenoma or ectopic ACTH [e.g. small cell lung cancer, carcinoid tumor]) ↓ ACTH (adrenal tumor, adrenal primary nodular hyperplasia) ↑ DHEAS ↑ cortisol	• More rapid appearance when due to an adrenal carcinoma or malignancy • Acne, central obesity, moon facies, buffalo hump, striae distensae, hypertension, impaired glucose tolerance
Acromegaly	↑ growth hormone ↑ insulin-like growth factor 1 (IGF-1)	• Coarse facial features, macrognathia, enlarged hands and feet, deepened voice, hyperhidrosis
Hyperprolactinemia	↑↑ prolactin	• Amenorrhea, galactorrhea, infertility
Thyroid disorders	↓ SHBG (hypothyroidism) Abnormal TSH	• Menstrual dysfunction • Thyroid dysfunction
Insulin resistance disorders (obesity-related and genetic syndromes)	↑ insulin (fasting) ↑ triglycerides Hyperglycemia	• Severe insulin resistance, impaired glucose tolerance • Acanthosis nigricans, acrochordons, virilization • Amenorrhea, infertility • Often polycystic ovaries on ultrasound • Metabolic syndrome
Drug-induced hirsutism		
• Exogenous androgens (topical, oral, injections) (e.g. danazol, testosterone, DHEA) • Anabolic steroids • Corticotropin (ACTH) • Glucocorticoids • Metyrapone • Progestins • Valproic acid		• Also consider the use of topical androgens by a patient's partner

*Rarely present with isolated hirsutism.

Table 70.6 Classification of types of hirsutism. More common entities are in **bold** font. Patients with liver disease can have a decrease in sex hormone binding globulin (SHBG), and a subsequent increase in free testosterone, which may exacerbate other causes of hirsutism. There is also conversion of androgens (e.g. Δ-4-androstenedione > testosterone) into estrogens in the ovaries and peripheral sites (adipose tissue, liver). In theory, a reduction in this conversion could lead to an increase in circulating androgens. ACTH, adrenocorticotropic hormone; DHEAS, dehydroepiandrosterone sulfate; FSH, follicle-stimulating hormone; LH, luteinizing hormone; TSH, thyroid-stimulating hormone.

Non-classic CAH (NCAH) presents postnatally, typically with onset during childhood or early adulthood; 17-hydroxyprogesterone levels are elevated but not high enough to be detected via newborn screening. Hirsutism represents the only manifestation in ~40%–60% of women with NCAH, which accounts for ~4% of all women with hirsutism. Premature pubarche is the most common presentation in children with NCAH, whereas female adolescents and women often develop acne, androgenic alopecia, irregular menses, and infertility as well as hirsutism.

Downloaded for Anonymous User (n/a) at Egyptian Knowledge Bank from ClinicalKey.com by Elsevier on March 10, 2024. For personal use only. No other uses without permission. Copyright ©2024. Elsevier Inc. All rights reserved.

Polycystic ovarian morphology may also be observed in NCAH; although virilization (Table 70.7) is more frequently evident in women with NCAH than in those with PCOS, measuring the serum 17-hydroxyprogesterone level is typically required to distinguish these two entities. Boys and men with NCAH less frequently seek medical attention for signs of androgen excess (e.g. early beard growth, large phallus)[40,41].

Tumoral adrenal hirsutism

Virilizing adrenal adenomas and carcinomas most often develop in postmenopausal women and may result in rapid onset and progression of hirsutism and virilization. Androgen-secreting carcinomas are more common than adenomas and typically produce both androgens and cortisol. Clinical findings may also include acne, androgenetic alopecia, amenorrhea, and features of Cushing syndrome (see below). Serum

Fig. 70.12 Familial hirsutism. Prolongation of the preauricular hair implantation line with terminal hairs of the lateral lower face and neck.

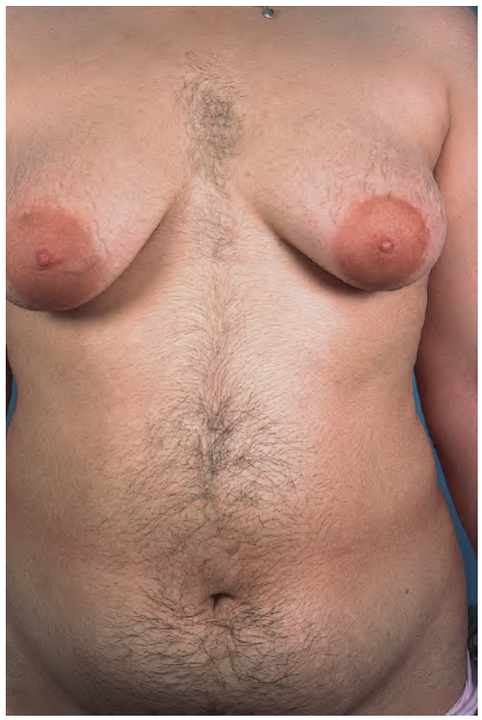

Fig. 70.13 Hirsutism in a young woman with polycystic ovary syndrome. Both lateral and central patterns are present.

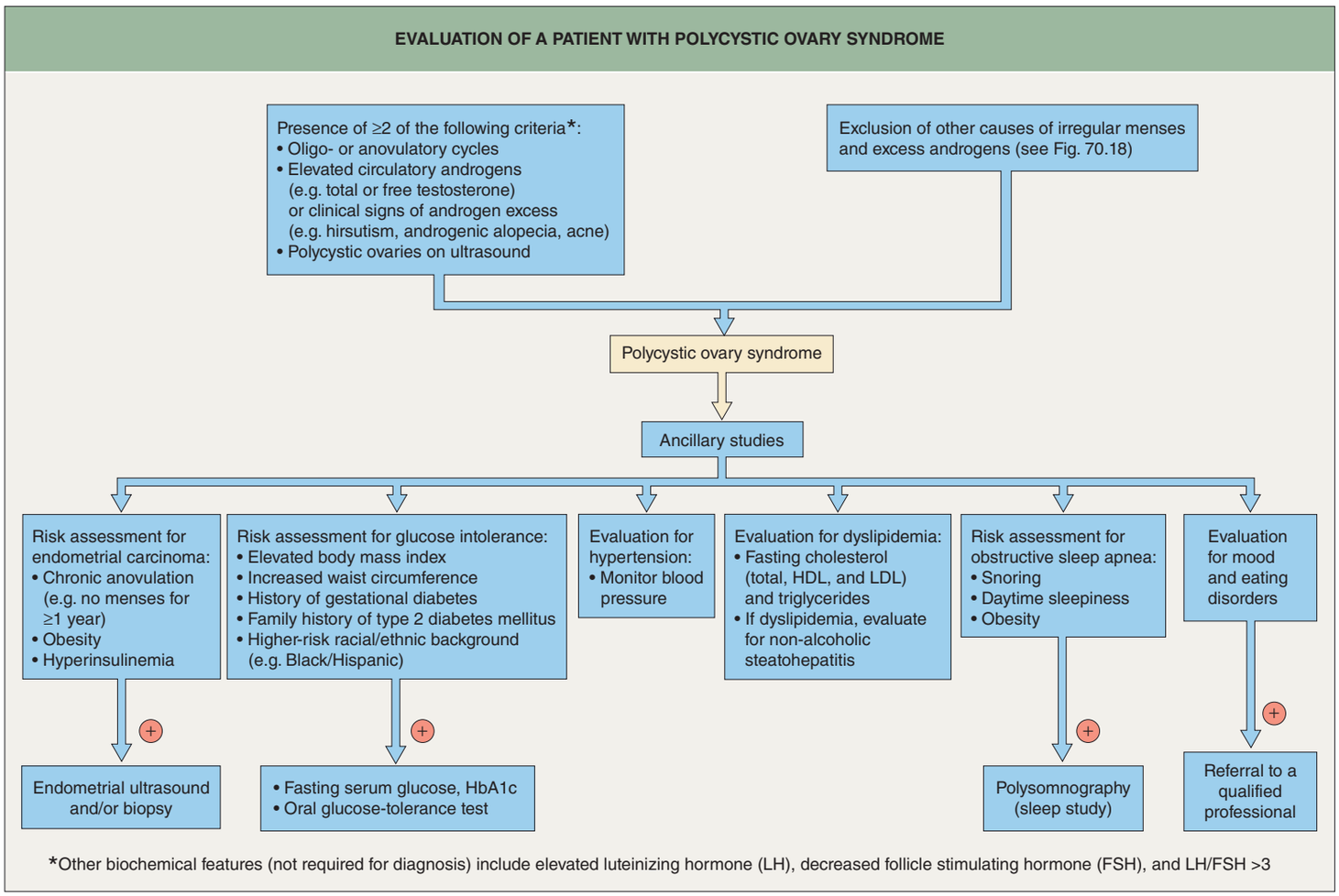

Fig. 70.14 Evaluation of a patient with polycystic ovary syndrome. Hb, hemoglobin; HDL, high-density lipoprotein; LDL, low-density lipoprotein. *Adapted from Ehrman DA. Polycystic ovary syndrome. N Engl J Med 2005;352:1223–36.*

Downloaded for Anonymous User (n/a) at Egyptian Knowledge Bank from ClinicalKey.com by Elsevier on March 10, 2024. For personal use only. No other uses without permission. Copyright ©2024. Elsevier Inc. All rights reserved.

levels of testosterone and DHEAS levels are markedly elevated, and serum cortisol may also be increased.

Other endocrinopathies associated with hirsutism

Other endocrinopathies in which women may develop hirsutism together with disease-specific manifestations include Cushing syndrome, hyperprolactinemia, acromegaly, thyroid disorders, and insulin resistance disorders[28]. Pregnant women may also present with hirsutism as a result of ovarian and placental androgen production.

Hypercortisolism (Cushing syndrome)

Cushing syndrome may be associated with either high plasma ACTH levels (pituitary hyperproduction or "ectopic ACTH syndrome") or a nearly complete lack thereof (adrenal primary nodular hyperplasia, adrenal adenoma, or adrenal carcinoma). All patients have an increase in plasma cortisol, which is the cause of the major clinical features: central obesity with "moon facies" and "buffalo hump", hypertension, glucose intolerance, purple striae, and ecchymoses. Patients with adrenal hyperplasia (usually due to ACTH hyperstimulation by a pituitary adenoma) or adrenal adenomas typically have an insidious onset of symptoms, but with an adrenal carcinoma or ectopic ACTH production by a malignant tumor, manifestations appear more rapidly. If there is significant production of androgens, which is not the norm for adrenal adenomas, virilization with hirsutism will be present in addition to the typical manifestations of Cushing syndrome.

Hyperprolactinemia

Hirsutism represents a rare manifestation of hyperprolactinemia, which is most often caused by pituitary adenomas and drugs (e.g. dopamine antagonists). This etiology of hirsutism should be considered in women <50 years of age who present with galactorrhea together with oligomenorrhea, amenorrhea, or infertility ("amenorrhea–galactorrhea syndrome").

Acromegaly

Acromegaly results from excess secretion of growth hormone (GH), most commonly by a pituitary adenoma. The clinical features reflect elevated serum concentrations of both GH and insulin-like growth factor 1 (IGF-1), which is GH dependent. Long-term excess of GH

Fig. 70.15 Facial hirsutism due to ovarian hyperthecosis. *Courtesy Robert Hartman, MD.*

DIFFERENCES BETWEEN DEFEMINIZATION AND VIRILIZATION	
Defeminization	**Virilization**
• Acne • Female pattern hair loss • Menstrual alterations (e.g. oligomenorrhea) • Breast atrophy and loss of female body contours • Decreased rugosity of the vaginal columns • Infertility	• Hirsutism • Male pattern hair loss • Amenorrhea • Muscle mass increased • Clitoromegaly • Coarsening of the voice

Table 70.7 Differences between defeminization and virilization.

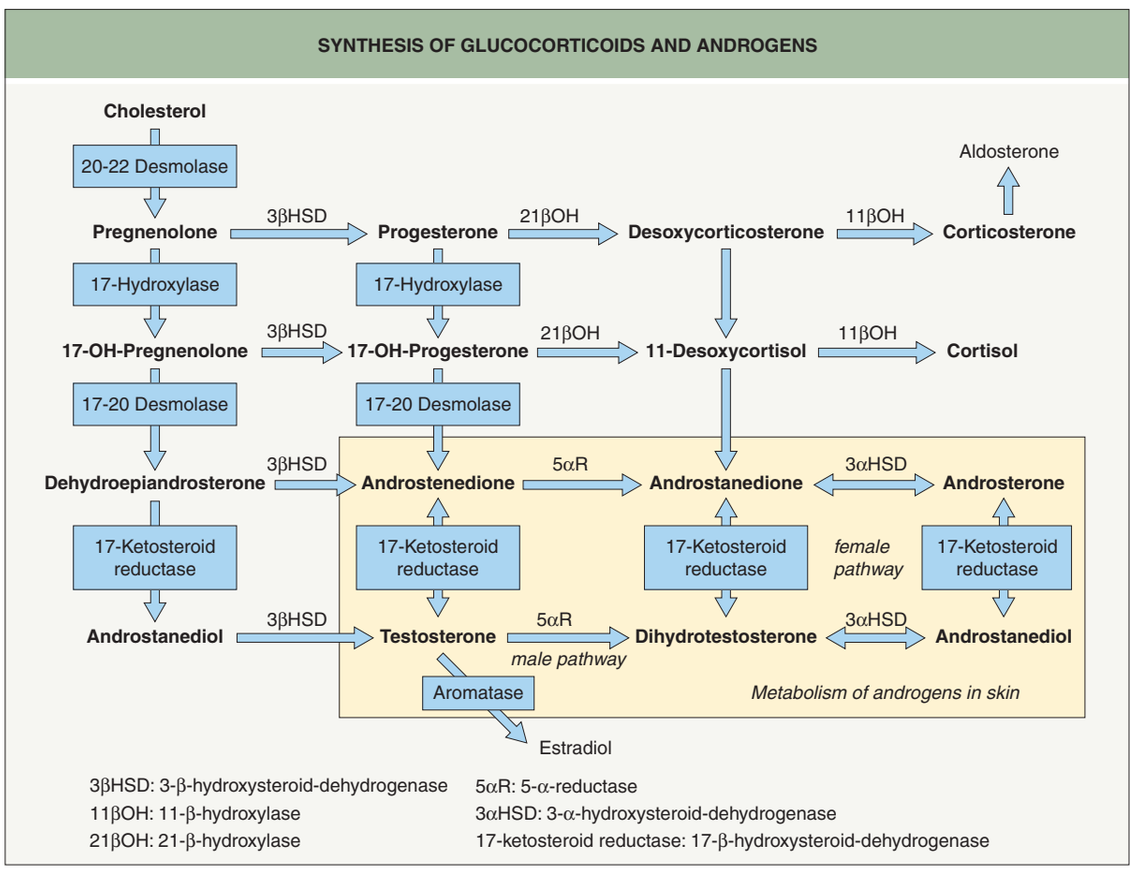

Fig. 70.16 Synthesis of glucocorticoids and androgens. The most common cause of congenital adrenal hyperplasia is 21-hydroxylase deficiency. This leads to an accumulation of 17-OH-progesterone.

Downloaded for Anonymous User (n/a) at Egyptian Knowledge Bank from ClinicalKey.com by Elsevier on March 10, 2024. For personal use only. No other uses without permission. Copyright ©2024. Elsevier Inc. All rights reserved.

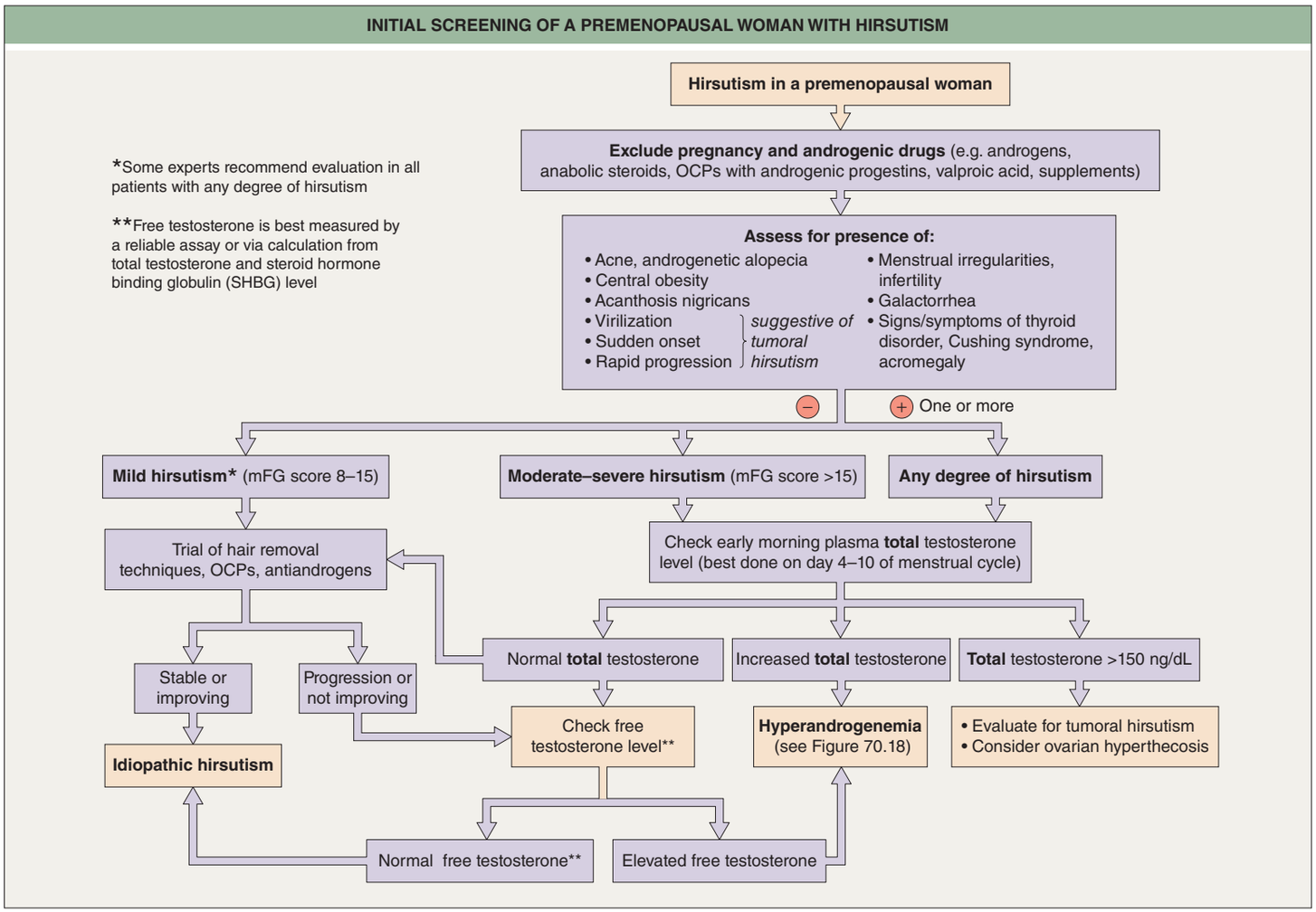

Fig. 70.17 Initial screening of a premenopausal woman with hirsutism. mFG, modified Ferriman and Gallwey; OCPs, oral contraceptives.

and IGF-1 results in overgrowth of many tissues and organs, including skin thickening as well as the classic findings of enlarged hands and feet, macrognathia, and macroglossia. Additional cutaneous manifestations can include hirsutism, hypertrichosis, hyperhidrosis, acanthosis nigricans, acrochordons, and cutis verticis gyrata.

Thyroid disorders

Thyroid dysfunction interferes with sex hormone metabolism and can result in irregular menstruation. Hypothyroidism can also cause cystic ovarian changes and decreased levels of sex hormone-binding globulin (SHBG), which increases the amount of free circulating testosterone.

Insulin-resistance disorders

Disorders of severe insulin resistance (e.g. obesity-related, insulin receptor mutations [*type A syndrome*], anti-insulin receptor antibodies [*type B syndrome*]) are often associated with hyperandrogenism, hirsutism, and even virilization[44,45]. Marked hyperinsulinemia results in ovarian hyperandrogenism, presumably via receptors for insulin and IGF-1 on ovarian theca cells. Insulin also decreases SHBG levels, thereby increasing the amount of free circulating testosterone. Ovaries often show a polycystic pattern on ultrasound.

Drug-induced hirsutism

Several drugs have been associated with the development of hirsutism (see Table 70.6). Identifying such culprit drugs and stopping them will typically result in reversal of the hirsutism.

Diagnosis

Hirsutism is a clinical diagnosis and a potential indicator of a hyperandrogenic disorder that may require treatment and have associated comorbidities such as metabolic syndrome or fertility issues. In a premenopausal woman with hirsutism, the mFG score (see Fig. 70.11) should be determined and assessment for associated findings initiated (Fig. 70.17). Additional evaluation of women with hyperandrogenemia for signs of PCOS are outlined in Figs. 70.18 and 70.14.

It is important to inquire about the age of onset (premenopausal vs postmenopausal), progression (rapid vs gradual), and emotional and psychosocial impact of the hirsutism. Patients should also be asked about their menstrual history (e.g. oligo- or amenorrhea), medications (see Table 70.6), comorbidities (e.g. insulin resistance disorders), ethnicity, and family history. Physical examination should determine if true hirsutism (versus hypertrichosis) is present as well as its severity (see Fig. 70.11). In addition, patients should be evaluated for additional findings of hyperandrogenism (e.g. acne, androgenic alopecia), virilization (see Table 70.7), acanthosis nigricans, central obesity, and manifestations of other endocrinopathies associated with hirsutism (see Table 70.6). An abrupt onset and rapid progression of hirsutism or the presence of virilization should raise suspicion for a more serious cause of androgen excess (e.g. an androgen-secreting tumor). Premenopausal women with hirsutism are most likely to have PCOS, idiopathic hirsutism or NCAH, whereas postmenopausal women with new onset hirsutism are more likely to have an androgen-secreting tumor or ovarian hyperthecosis.

In a *premenopausal* woman with hirsutism, serum total testosterone is recommended as the initial biochemical study[28]. Additional considerations include measuring the serum 17-hydroxyprogesterone level (e.g. in women at higher risk of NCAH based on ethnicity or family history) and transvaginal pelvic ultrasonography to assess for PCOS. Additional evaluation based upon these results and the clinical presentation are outlined in Figs. 70.17 and 70.18. Of note, in women taking an oral contraceptive (OCP) or spironolactone, the results of laboratory testing

Downloaded for Anonymous User (n/a) at Egyptian Knowledge Bank from ClinicalKey.com by Elsevier on March 10, 2024. For personal use only. No other uses without permission. Copyright ©2024. Elsevier Inc. All rights reserved.

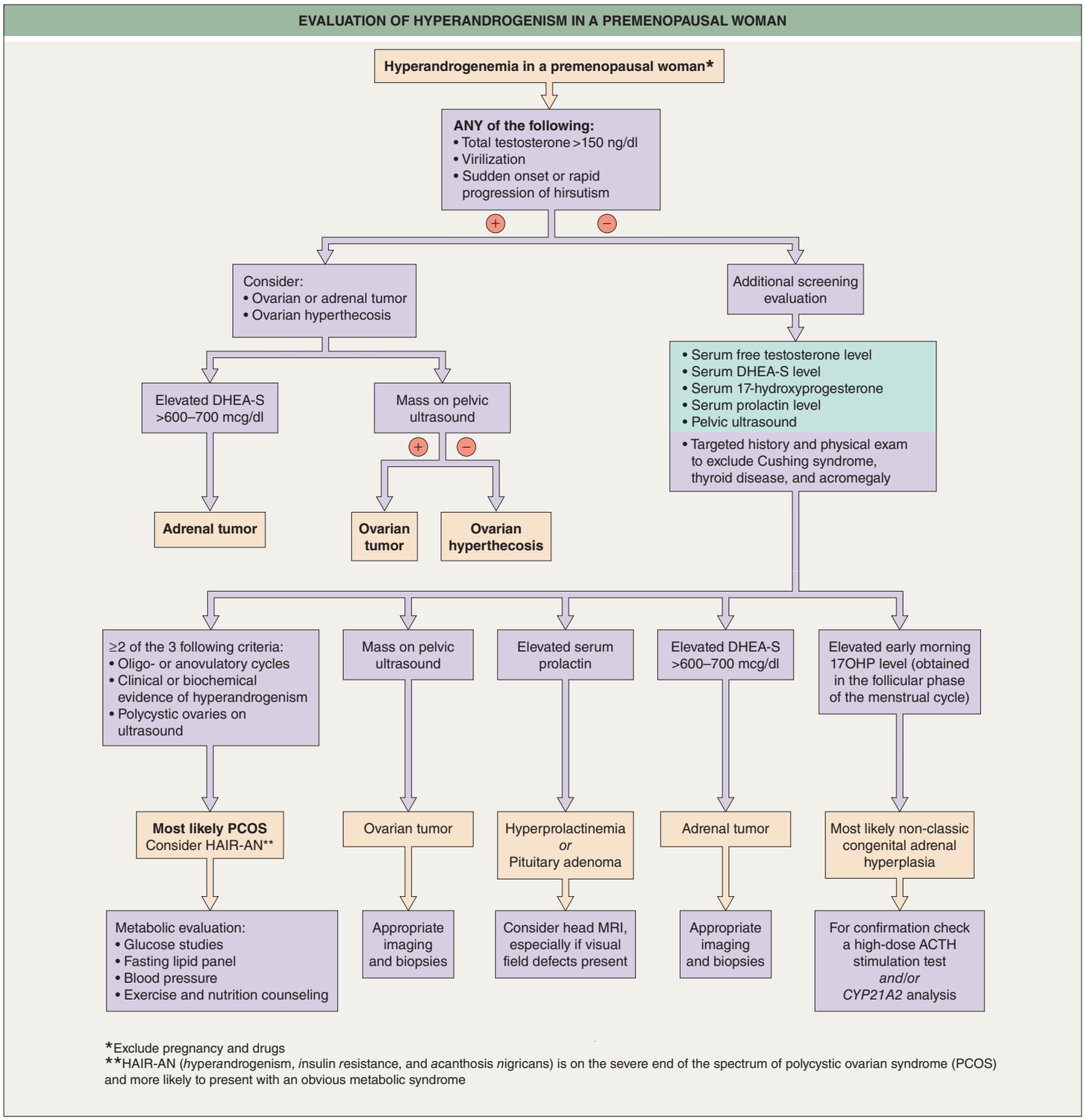

Fig. 70.18 Evaluation of hyperandrogenemia in a premenopausal woman.

will not be reliable. If an evaluation is desired, then discontinuation of the medications for at least 8–12 weeks is recommended.

The most useful biochemical tests to evaluate a *postmenopausal* woman with hirsutism are serum total testosterone and DHEAS levels. Serum total testosterone levels >150 ng/dl are suggestive of an androgen-secreting tumor, with higher testosterone levels typically associated with an ovarian source and DHEAS >700 mcg/dl suggestive of an adrenal source. Hyperandrogenism due to PCOS or NCAH can persist into menopause, and a serum 17-hydroxyprogesterone level should be considered if not evaluated previously. Other laboratory testing depends upon the presence of signs or symptoms suggestive of another endocrinopathy (see Table 70.6).

Treatment

The impact of hirsutism on a woman's quality of life should be assessed and regardless of the mFG score, treatment should be initiated if it is causing distress to the patient ("patient-important" hirsutism)[28]. Management of premenopausal and postmenopausal hirsutism involves a combination of systemic pharmacologic therapies (Table 70.8) and direct hair removal methods, both of which should be offered to women with "patient-important" hirsutism. Bilateral oophorectomy can be considered in the management of ovarian hyperthecosis. In the case of ovarian and adrenal tumors, surgical intervention is usually required.

Downloaded for Anonymous User (n/a) at Egyptian Knowledge Bank from ClinicalKey.com by Elsevier on March 10, 2024. For personal use only. No other uses without permission. Copyright ©2024. Elsevier Inc. All rights reserved.

TREATMENT OF HIRSUTISM AND HYPERANDROGENISM – SYSTEMIC AGENTS AND CLINICAL SCENARIOS		
Systemic agents		
Combined oral contraceptives (cOCPs)* • All cOCPs appear to have similar effectiveness for treating hirsutism • For women at higher risk for VTE (e.g. obesity, age ≥40 years), select a cOCP with the lowest effective dose of ethinyl estradiol (usually 20 mcg) and a low-risk progestin (e.g. norethindrone, norgestimate) **Antiandrogens**† • Spironolactone 100–200 mg/day (usually given in divided doses, twice daily; see Ch. 36) • Cyproterone acetate 50–100 mg/day (given on days 5–15 of menstrual cycle)‡ • Finasteride 2.5–5 mg/day • Bicalutamide 50 mg/day (occasional hepatotoxicity) • Flutamide (not recommended because of hepatotoxicity risk) **Gonadotropin-releasing hormone (GnRH) agonists** (risk of severe estrogen deficiency; *typically reserved for severe hirsutism [e.g. ovarian hyperthecosis] that is unresponsive to combined OCPs + antiandrogen therapy*) **Insulin-lowering agents** – metformin > thiazolidinediones (improve metabolic syndrome and reproductive function but not useful as monotherapy for hirsutism) **Glucocorticoids** – e.g. low-dose hydrocortisone, prednisone, or dexamethasone (*second-line treatment for NCAH*)		
Clinical scenarios and recommended treatment¶		
Premenopausal female	**First-line**§: cOCP **Second-line**: cOCP + spironolactone or cyproterone acetate‡	**Severe or refractory:** finasteride or GnRH agonist plus cOCP or other contraceptive method
Postmenopausal female	**First-line**: spironolactone or cyproterone acetate‡	
NCAH	**First-line:** cOCP ± spironolactone or cyproterone acetate‡ **Second-line or if seeking ovulation induction**: glucocorticoid	

*Avoid in women with a history of VTE, inherited thrombophilia, smoking (if age >35 years), migraine with aura, or an estrogen-dependent neoplasm.
†Because of teratogenicity, not recommended as monotherapy in sexually active women of reproductive age unless a reliable contraceptive method is used.
‡CPA is not available in the United States; ethinylestradiol 20–35 mg is also typically given on days 5–25 of the menstrual cycle in premenopausal women.
¶A waiting period of 6 months is recommended after initiating a treatment and before adding or changing medications.
§In patients with severe hirsutism causing emotional distress and/or previous history of treatment failure with combined OCP, consider first-line treatment with a cOCP + antiandrogen.

Table 70.8 Treatment of hirsutism and hyperandrogenism – systemic agents and clinical scenarios. For hirsute women with obesity, including those with polycystic ovary syndrome (PCOS), lifestyle changes (e.g. diet, exercise) are also recommended. NCAH, non-classic congenital adrenal hyperplasia; VTE, venous thromboembolism.

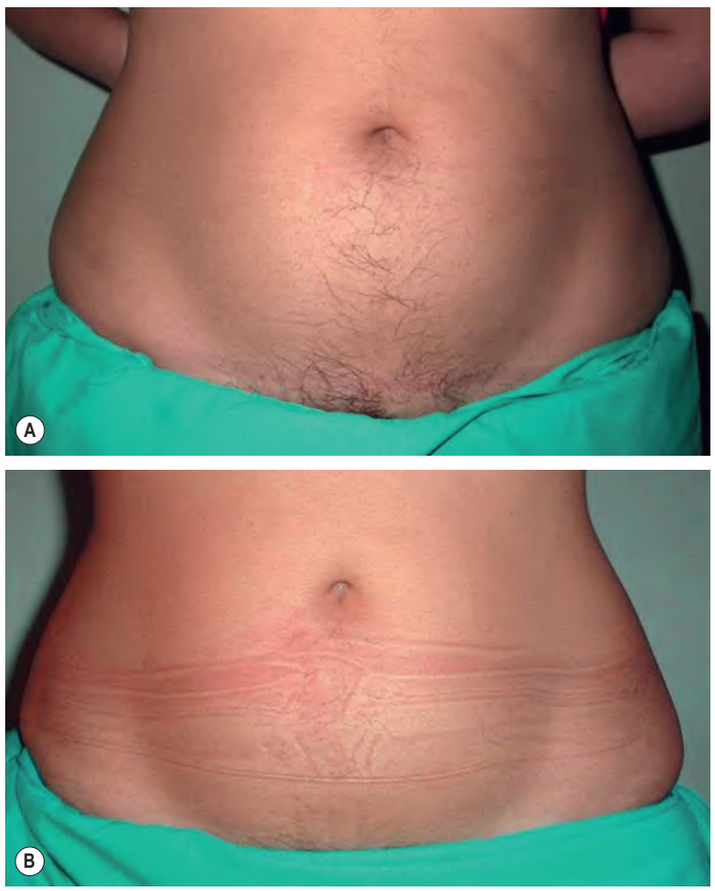

Fig. 70.19 Hirsutism before (A) and after treatment (B) with antiandrogen therapy. This patient had the SAHA (*s*eborrhea, *a*cne, *h*irsutism, and *a*lopecia) syndrome and achieved clinical improvement in hirsutism after one year of antiandrogen therapy.

Systemic therapy

The 2018 Endocrine Society clinical guidelines[28] recommend initial treatment with systemic pharmacologic therapy in *premenopausal* "patient-important" hirsutism that persists despite cosmetic measures. They suggest a combined estrogen–progesterone OCP as first-line treatment, as long as fertility is not immediately desired and there are no contraindications (e.g. history of venous thromboembolism [VTE], inherited thrombophilia, smoking if age >35 years, migraine with aura, estrogen-dependent neoplasm). Combined OCPs (cOCPs) suppress LH secretion and thus ovarian androgen production. They also stimulate the production of SHBG, which results in a decrease of circulating free androgen levels. The Endocrine Society guidelines do not recommend one cOCP over another for treating hirsutism based on a meta-analysis of effectiveness[28,46,47]. Although cOCPs containing antiandrogenic progestins (e.g. drospirenone, cyproterone acetate [not available in the US]) have been shown in some studies to lower mFG scores slightly more than other combined OCPs, the difference is not thought to be clinically important[46]. A cOCP containing the lowest effective dose of ethinyl estradiol (usually 20 mcg) and a low VTE-risk progestin (e.g. norgestimate, norethindrone) is recommended in women at higher risk for VTE (e.g. obesity, age ≥40 years)[28]. Although levonorgestrel is associated with a low VTE risk, this progestin is the most androgenic and may have adverse metabolic effects, making it less suitable for patients with PCOS[28].

If the clinical response is not achieved after 6 months of a cOCP, then an antiandrogen (e.g. spironolactone) can be added (see Ch. 36). A trial of at least 6 months is suggested before making dose adjustments or medication changes (Fig. 70.19)[28]. Antiandrogen monotherapy is not advised unless the patient is using adequate contraception, given the risk of impact on a developing fetus. If the hirsutism is severe or previous use of a cOCP has been unsuccessful, then initial therapy with both a cOCP and antiandrogen can be considered.

Additional systemic treatment options for hirsutism are summarized in Table 70.8. Flutamide and bicalutamide are nonsteroidal androgen receptor blockers that are approved for the treatment of prostate cancer. Although both of these agents have been utilized for the treatment of hirsutism, flutamide is not recommended for this indication because of its higher potential for hepatotoxicity. Insulin-lowering

Downloaded for Anonymous User (n/a) at Egyptian Knowledge Bank from ClinicalKey.com by Elsevier on March 10, 2024. For personal use only. No other uses without permission. Copyright ©2024. Elsevier Inc. All rights reserved.

medications (e.g. metformin) have not shown efficacy as monotherapy for hirsutism[28]. Management of PCOS comorbidities are outlined in Fig. 70.14. Lifestyle modifications (e.g. diet, exercise) are recommended for all hirsute women with obesity[28,31]. Lastly, for women with NCAH, glucocorticoids may be utilized to treat hirsutism that does not respond adequately to a cOCP ± antiandrogen or to induce ovulation.

In *postmenopausal* women with "patient-important" hirsutism and no evidence of an androgen-secreting tumor, treatment typically includes an antiandrogen plus direct hair removal methods (see Table 70.8).

Topical therapy

Topical antiandrogen therapy (e.g. canrenone [active metabolite of spironolactone], finasteride) is generally not recommended for treatment of hirsutism because of limited evidence of efficacy. A newer topical antiandrogen, clascoterone, has been approved for the treatment of acne but has yet to be studied for hirsutism.

Eflornithine HCL 13.9% cream is FDA-approved for the reduction of unwanted facial hair in women; it was discontinued by the original manufacturer in 2023. It irreversibly inhibits ornithine decarboxylase, an enzyme that catalyzes the rate-limiting step in follicular polyamine synthesis, which is necessary for hair growth. In a randomized vehicle-controlled study in 594 women, it was shown to reduce hair length and mass by ~25%[48]. Because eflornithine HCL slows hair growth rather than removes hair, it is best used and more effective in conjunction with other direct hair removal methods (e.g. laser or intense pulsed light [IPL])[49]. Results can take up to 8 weeks to become evident, and hair gradually returns to pretreatment levels upon discontinuation.

Direct hair removal methods

Direct hair removal methods can either remove a portion of the hair from above the skin's surface (depilation) or the entire hair shaft (epilation)[50]. Epilation methods may result in temporary or potentially permanent hair reduction. Each hair removal option has advantages and disadvantages[50].

Depilation methods include trimming, shaving, dermaplaning, and chemical depilatories. Shaving is easy and inexpensive but must be done frequently and can cause skin irritation. Contrary to popular belief, shaving does not change the texture, color, or growth rate of hair. It does, however, create a blunt tip upon regrowth that can give the illusion of thicker hair. Chemical depilatory agents, which dissolve the hair shafts via breakage of disulfide bonds, can be used for large areas but often cause skin irritation.

The results of epilation typically last longer than those of depilation. Tweezing, threading, waxing, and sugaring are effective temporary epilation techniques, but they are painful and often impractical for larger areas. Potentially permanent options include electrolysis and photoepilation utilizing a laser or IPL. Although effective, electrolysis is painful, time-consuming, and not practical for treating large areas (see Ch. 140). Photoepilation, which can treat larger areas in a shorter amount of time, represents the preferred option for long-term hair removal[27]. It utilizes pulses of light absorbed by melanin to destroy pigmented terminal hair follicles through thermal damage. Photoepilation systems include alexandrite, diode, and Nd:YAG lasers and various IPL sources, which are selected based upon the patient's skin and hair color (see Ch. 137). Clinical trials have shown ~40%–80% hair reduction, depending upon the device used and the number of treatments provided[51,52]. Photoepilation is ineffective for blond, white, or gray hairs and can be costly and painful, with potential side effects including pigmentary changes and rarely scarring or paradoxical hypertrichosis[19].

Additional figures and tables on Abraham's classification of hirsutism, and Methods to reduce unwanted hair, available in our eBook (see inside front cover for access code).

eFig. 70.1 Becker melanosis (nevus). Both hyperpigmentation and hypertrichosis are present. *Courtesy Jean L. Bolognia, MD.*

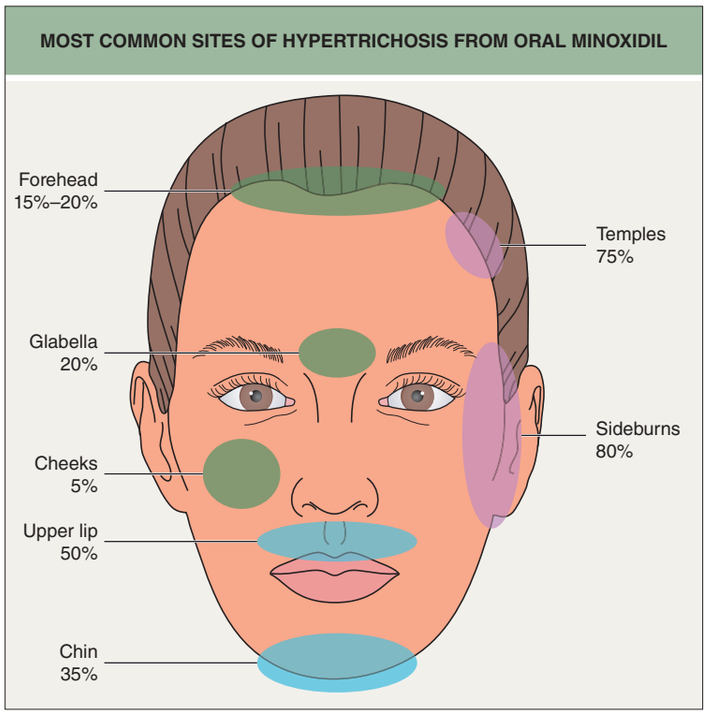

eFig. 70.3 Most common sites of hypertrichosis from oral minoxidil. *Adapted from Jimenez-Cauhe J, Saceda-Corralo D, Rodrigues-Barata R, et al. Characterization and management of hypertrichosis induced by low-dose oral minoxidil in the treatment of hair loss. J Am Acad Dermatol 2021;84:222–3.*

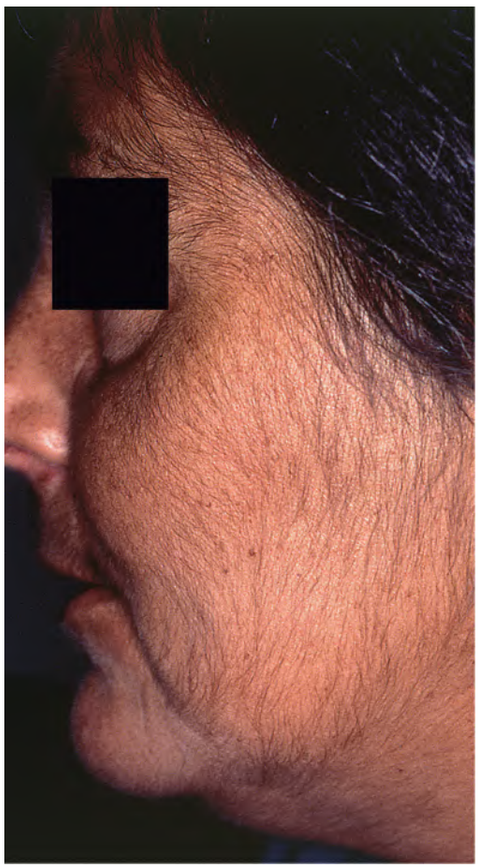

eFig. 70.2 Facial hypertrichosis in a woman due to porphyria cutanea tarda.

eFig. 70.4 Hypertrichosis secondary to oral minoxidil. *Courtesy Eugene Mirrer, MD.*

Downloaded for Anonymous User (n/a) at Egyptian Knowledge Bank from ClinicalKey.com by Elsevier on March 10, 2024. For personal use only. No other uses without permission. Copyright ©2024. Elsevier Inc. All rights reserved.

eFig. 70.5 "Pseudo"-hypertrichosis occurring in an umbilical pilonidal sinus (cyst). Localized "pseudo"-hypertrichosis can occur within a pilonidal sinus (cyst), usually located within the gluteal cleft and rarely elsewhere, e.g. umbilicus, as seen here (**A**). However, hairs are easily extracted (**B**). *Courtesy Karynne O. Duncan MD*.

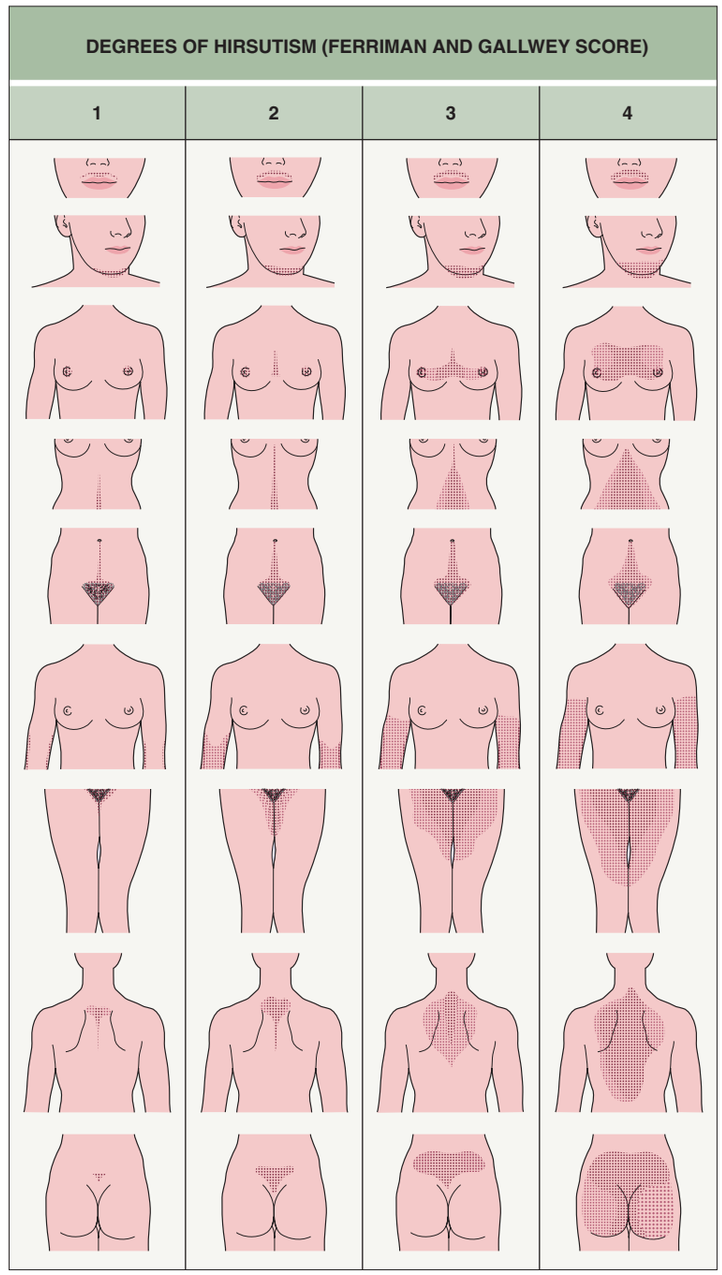

eFig. 70.6 The modified Ferriman–Gallwey (mFG) hirsutism scoring system – nine sites of assessment. The modified Ferriman and Gallwey score is based upon the sum of the values (graded from 0 to 4 points) for each of the nine body areas illustrated as follows: 0 points (no terminal hairs); 1 point (minimal terminal hairs); 2 points (hair growth is more than minimal but not yet that of a man); 3 points (hair growth is that of a man who is not very hairy); and 4 points (equivalent to a very hairy man). Total mFG scores that define hirsutism in reproductive-aged women vary depending upon race/ethnicity and are as follows: US and United Kingdom White or Black women, ≥8 (scores between 8 and 15 generally considered mild, 16–25 moderate, and >25 severe hirsutism); Mediterranean, Middle Eastern and Hispanic women, >9–10; South American women, ≥6; and Asian women, ranging from ≥2 for Han Chinese women to ≥7 for Southern Chinese women.

Downloaded for Anonymous User (n/a) at Egyptian Knowledge Bank from ClinicalKey.com by Elsevier on March 10, 2024. For personal use only. No other uses without permission. Copyright ©2024. Elsevier Inc. All rights reserved.

eFig. 70.7 Acquired hypertrichosis lanuginosa. *Courtesy Jeffrey P. Callen, MD.*

ABRAHAM'S CLASSIFICATION OF HIRSUTISM	
Score	**Classification**
<8	Normal
8–16	Discrete
17–25	Moderate
>25	Important

eTable 70.1 Abraham's classification of hirsutism. Based on the Ferriman and Gallwey score.

METHODS TO REDUCE UNWANTED HAIR		
Camouflage	**Direct hair removal methods**	**Retardation of hair growth**
• Lightening of hair with bleaching product	***Depilation*** ***Chemical*** • Barium sulfate creams* • Calcium thioglycolate creams ***Mechanical*** • Trimming • Shaving • Dermaplaning ***Epilation*** • Tweezing • Waxing • Threading • Sugaring • Electrolysis† • Thermolysis† • Lasers (e.g. Nd:YAG, diode, alexandrite) or IPL	• Eflornithine HCL (13.9%) cream (best used in conjunction with other hair removal techniques); discontinued by the original manufacturer
*More effective than calcium thioglycolate but more irritating and odiferous. †Potential for permanent hair removal.		

eTable 70.2 Methods to reduce unwanted hair. The results of epilation typically last longer than those of depilation. Chemical depilatories work by dissolving hair shafts via breakage of disulfide bonds. IPL, intense pulsed light.

Downloaded for Anonymous User (n/a) at Egyptian Knowledge Bank from ClinicalKey.com by Elsevier on March 10, 2024. For personal use only. No other uses without permission. Copyright ©2024. Elsevier Inc. All rights reserved.